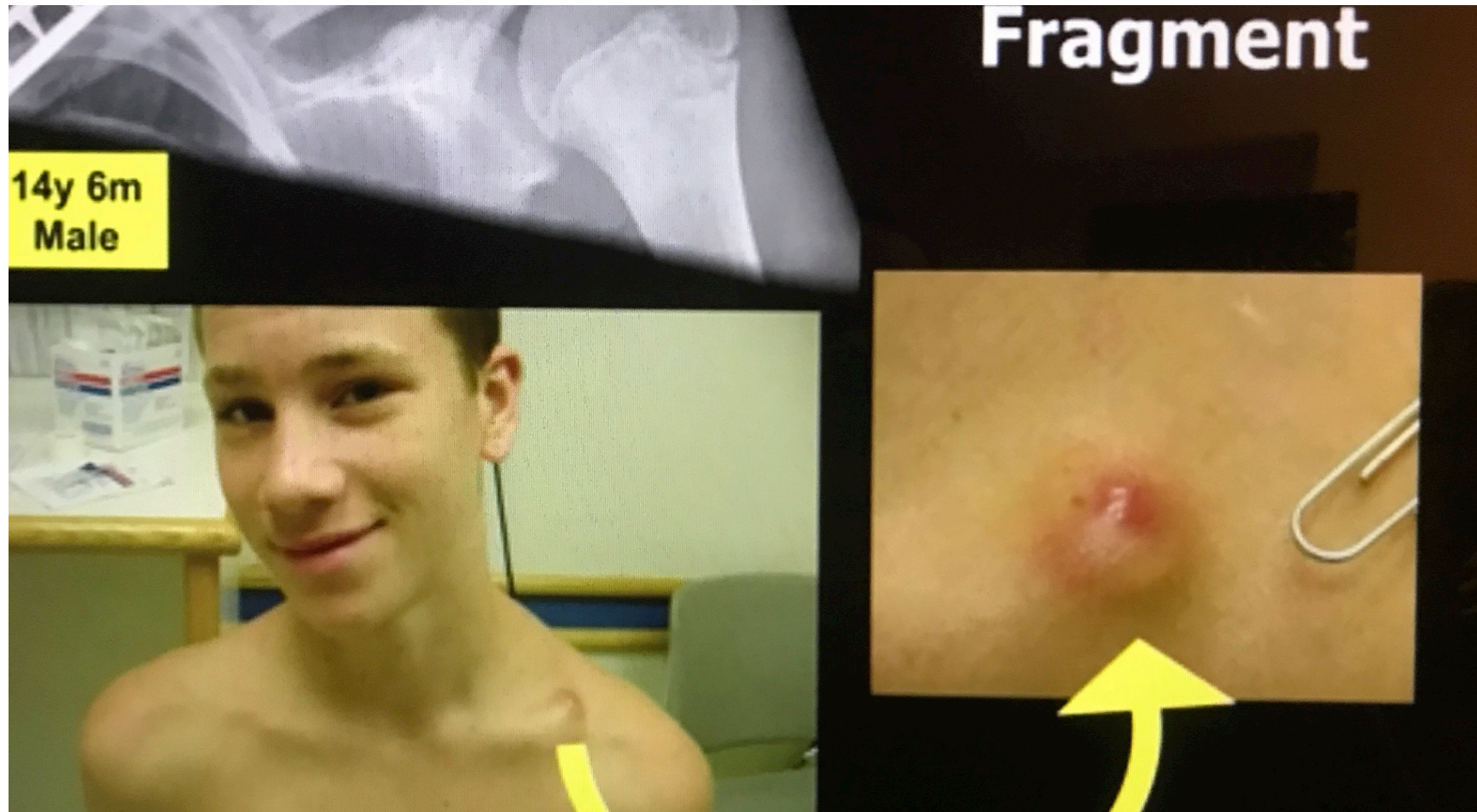

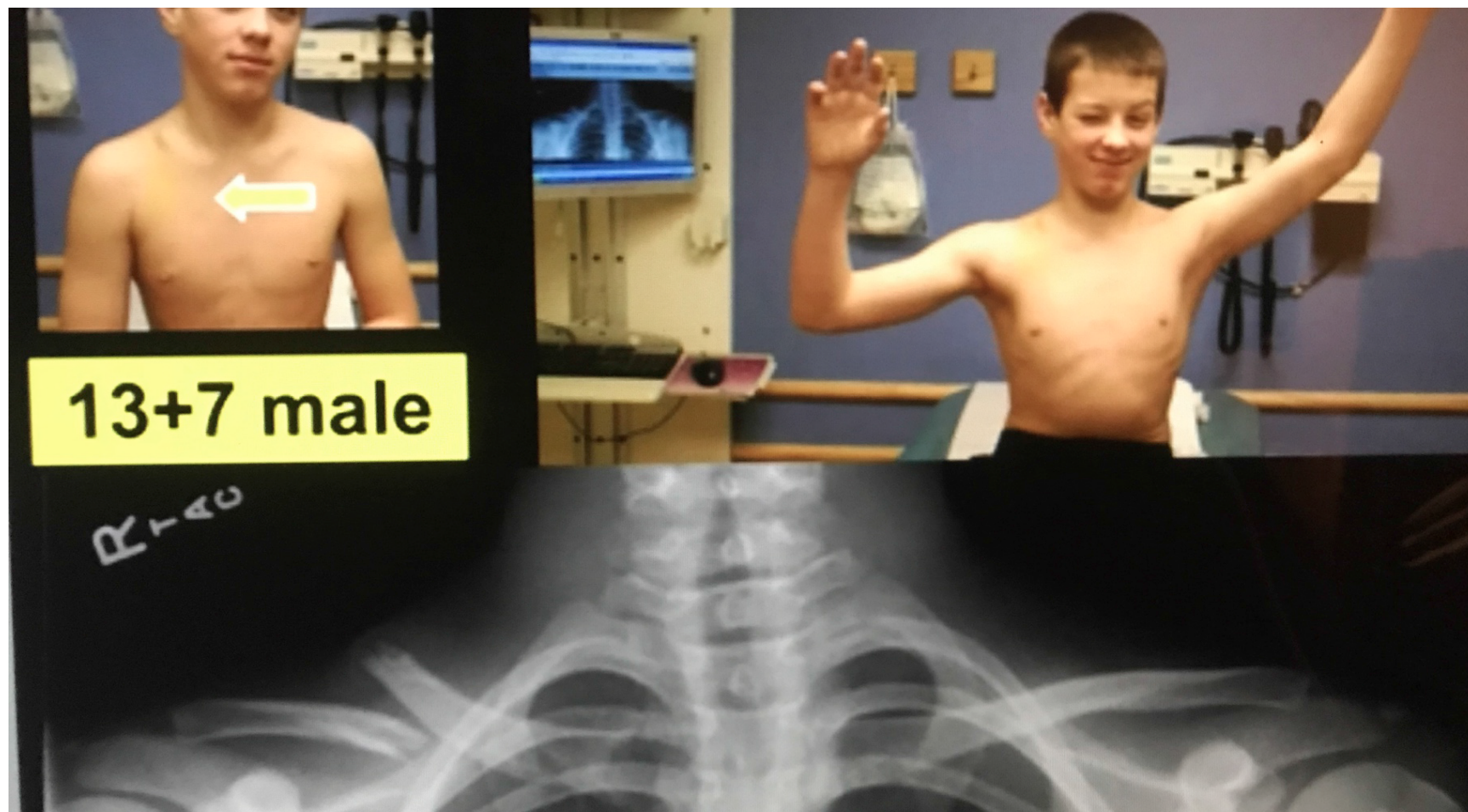Complications des fractures de la clavicule

Dr Jean BENRAHHO
Polyclinique des Alpes de sud
05000 GAP
jbenrahho@clinalpsud.com

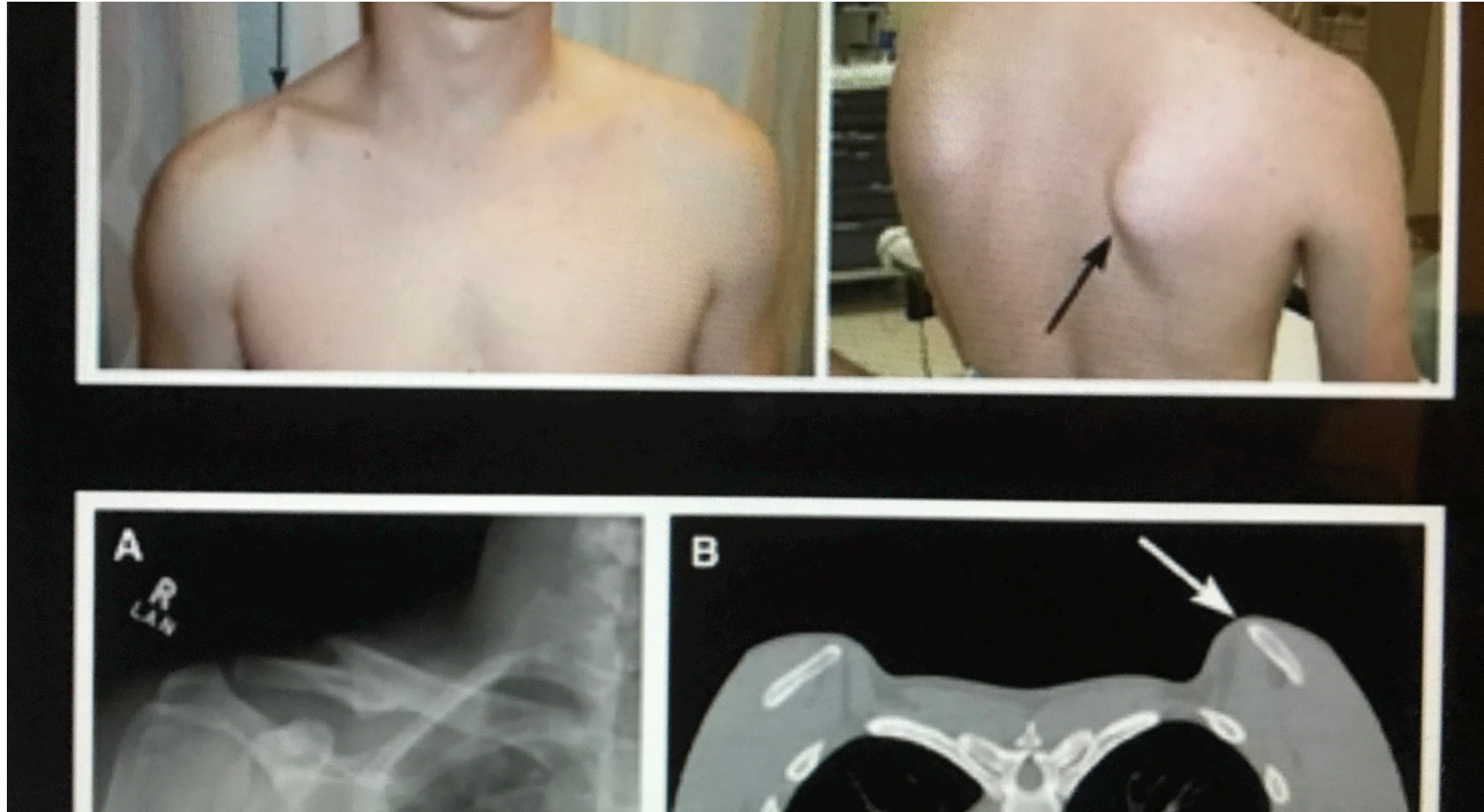
Risque du traitement orthopédique
ouverture du foyer de fracture par un
fragment clavicule



Limitation de la mobilité

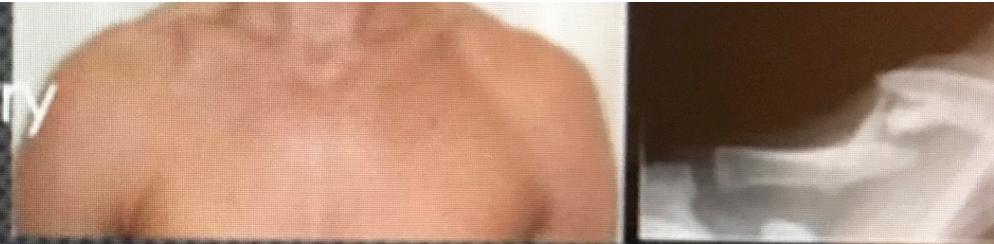

Dyskinésie scapulaire

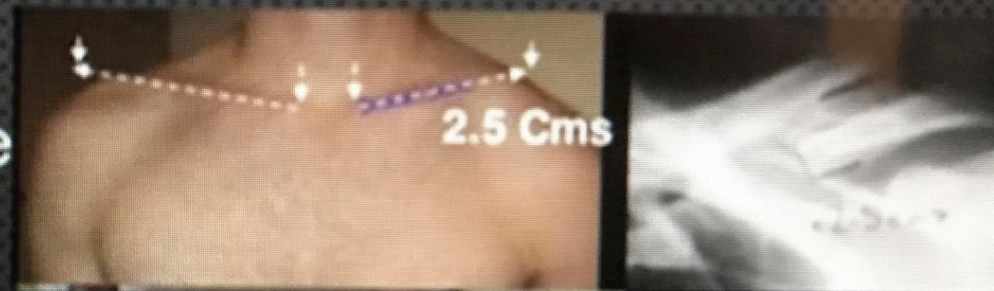


Troubles morphologiques

Shoulder Asymmetry



Shortened Clavicle



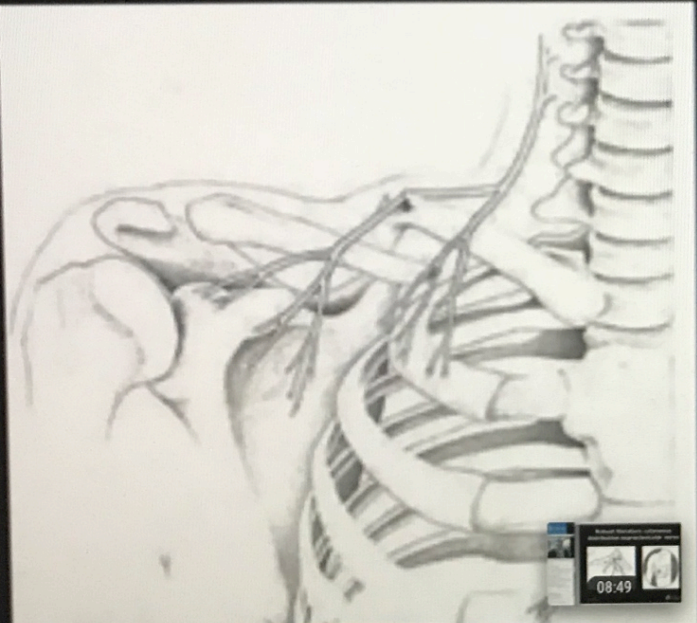
Mal-rotation



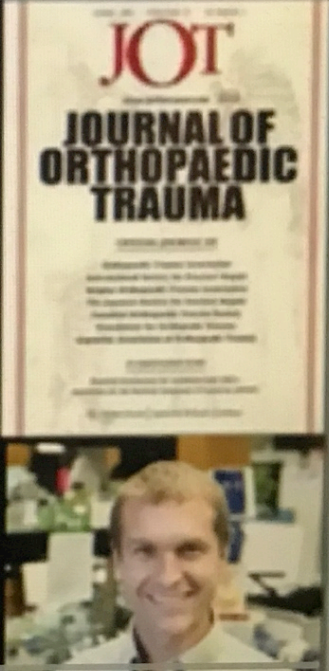
Lésion du nerf suprascapulaire

Supraclavicular Nerve Entrapment and Clavicular Fracture

Kevin O'Neill, MD, Christopher Stutz, MD,* Matthew Duvernay, PhD,†
and Jonathan Schoenecker, MD, PhD*†‡*



**16 y/o male
Lacrosse
player
(severe pain
noted before
surgery)**



08:49

Pedro Labronici et al

*Clavicular fracture ; incidence of supraclavicular nerve injury ; Rev.bras orth vol 8 N°4 , 2013

Eric HAVET , Fabrice Duparc et al

*Morphometric study of the shoulder and subclavicular innervation by the intermediate and lateral branches of supraclavicular nerve; surgical and radiologic anatomy , decembre 2007; volume 29; p 605-610

*Trajet anormal transclaviculaire d'une branche des nerfs supraclaviculaires

JYL CAFFINIER , chiru pédiat. 20; 279-381

Compression du plexus par un cal hypertrophique

Fracture callus

Jesse B. Jupiter, MD,^{a,b} and Matthew I. Leibman, MD,^{a,c} Boston and Newton, MA

2007

The close proximity of the supraclavicular nerves to the clavicle renders them vulnerable to injury in association with clavicle fractures or operative exposure of the clavicle. Presenting symptoms of supraclavicular nerve injury may extend from altered sensibility, located only in the dermatome of the involved nerve branch, to diffuse hyperesthesia resembling a complex regional pain syndrome.²⁻⁵

Few reports exist regarding supraclavicular nerve injury, with recommendations for treatment ranging from nonoperative treatment featuring stellate ganglion blocks⁴ to operative resection of the involved nerve.^{2,4}

The purpose of this report is to note the successful outcome after neurolysis of a supraclavicular nerve compressed by fracture callus.

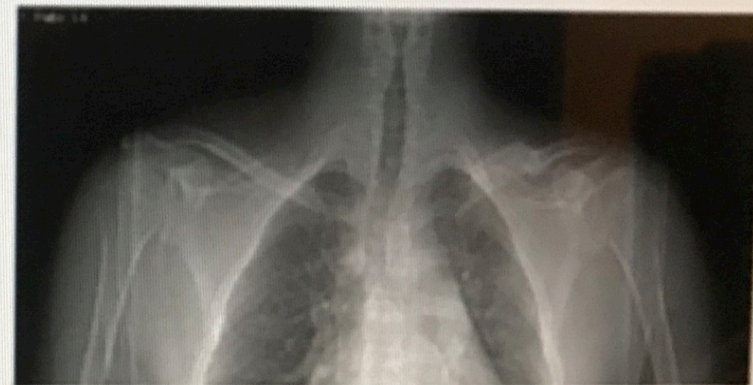

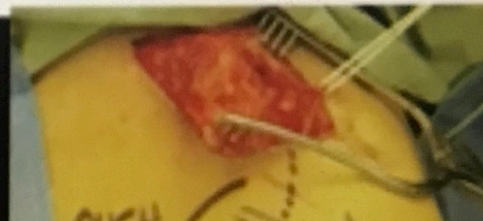


Figure 1 Anterior radiograph of healed clavicle fracture.

- 26 y/o male had surgery @
7 w after Rugby fracture



Retard de consolidation et pseudarthrose

