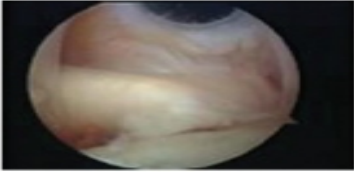
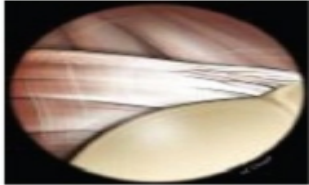

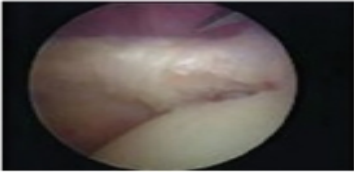
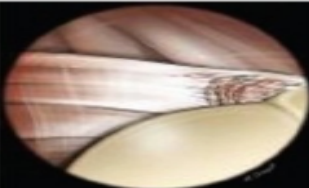

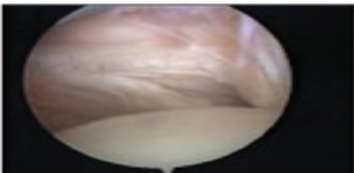
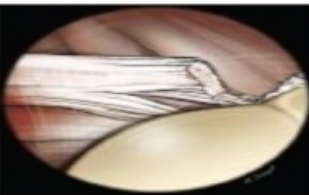

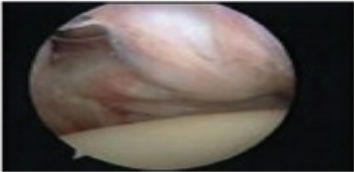


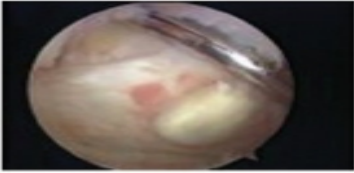



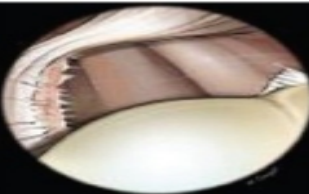



Lésions du sous scapulaire classification

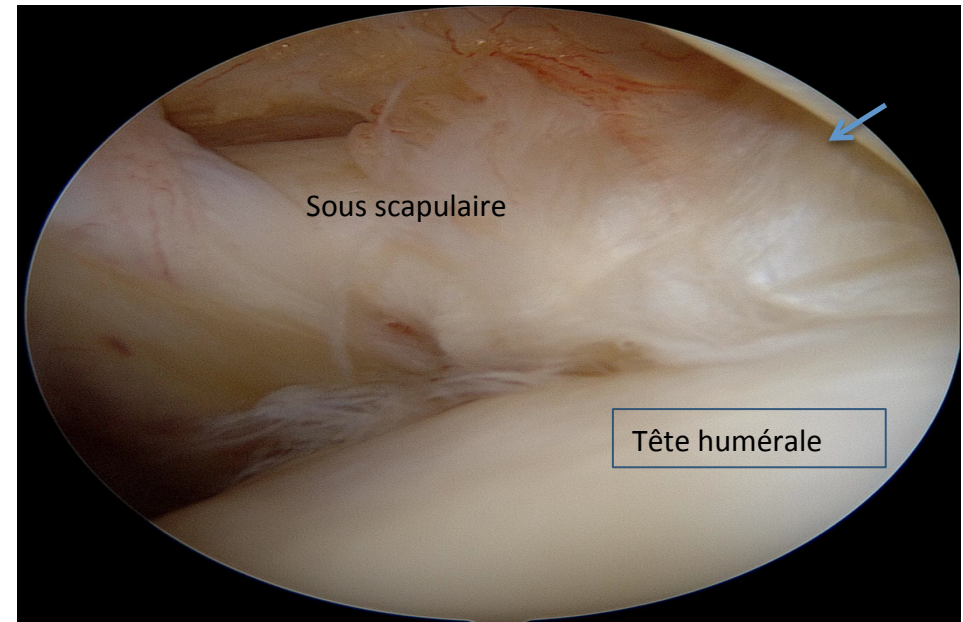
Lésion Type 1A et 1B

Classification des lésions dégénératives du sous scapulaire

	Description	Arthroscopic image	Drawing of Arthroscopic view	Drawing of anterior Anatomic view
Grade Ia	Minor fraying at the insertion site			
Grade Ib	Partial tears of the deep fibers at the insertion onto the lesser tuberosity			
Grade II	Complete tear of superior 1/3			
Grade III	Complete tear of superior 2/3			
Grade IV	Complete tear with retraction, no subluxation of humeral head			
Grade V	Complete tear with retraction, anterior subluxation of humeral head			

Type IA: **Lésion du sous scapulaire**

Lésion des fibres médiales du sous scapulaire
Ces lésions sont cachées il faut aller les chercher



type 1B **Lésion de sous scapulaire** Rupture des faisceaux profonds respectant la partie externe du tendon restant normalement inséré

